

Treatment of dental recessions in the esthetic zone by gingival and osseous recontouring. A multidisciplinary perio-prosthetic case report.

MU Dr. Daniel Urban, PhD.

Mint Dental, Private Dental Practice,
Ostravska 8, 040 11 Kosice, Slovakia

E-mail: daniel@mintdental.sk

ORCID: <http://orcid.org/0000-0002-0076-572X>

MD Dr. Renata Urban

Institution: Pavol Jozef Safarik University,
Faculty of Medicine, 1st Department of Dentistry,
Trieda SNP 1, 040 11 Kosice, Slovakia

E-mail: renata.urban@upjs.sk

ORCID: <http://orcid.org/0000-0002-6638-5463>

Corresponding author

Daniel Urban

daniel@mintdental.sk

Abstract

This case report describes an alternative treatment modality for the management of gingival recessions in the esthetic zone. Clinical problems set at the perio-prosthetic interface require multidisciplinary approach, one that considers multiple variables. Among them a clear understanding of biological width, gingival biotype, post-surgical healing process, need for temporization and a sound design of fixed restoration. In this case, stable gingival recontouring was accomplished by mucoperiosteal flap and resective osseous surgery followed by fabrication of a zirconia-based ceramic bridge. We conclude that in some cases resective approach in the treatment of gingival recessions may offer more favorable and predictable results compared to regenerative techniques.

Key words: gingival recession, gingival recontouring, zirconia-based bridge, biological width, gingival biotype

1. Introduction

There are no clear guidelines that describe a standardized approach in management of cases positioned at the perio-prosthetic interface. The current scientific evidence may be ambiguous and confusing. For these reasons the decision-making process involved in handling of these cases may often lead to a diverse and sometimes unexpected treatment outcomes. Some treatment modalities present a direct and well-defined relationship between the procedure and the expected outcome. Such treatments are considered predictable. Management of gingival recessions proves to be much less predictable. Prognostic factors may be of some benefit when trying to determine the probable treatment outcome. Pini-Prato (1) argues that this may not be the case when considering gingival recessions. The anticipation of 100% root coverage does not mean that it will occur. And data in the periodontal literature support this when reporting complete root coverage results ranging from 40% to 90% (2,3). Zucchelli et al. also claim that although each root coverage procedure can be performed by using a variety of techniques, the most critical factor is the technique's predictability (3). Another important aspect that we need to take into consideration are the patient's expectations. Laupacis (4) describes prognostic factors as "the characteristics of a particular patient which can be used to more accurately predict the patient's eventual outcome". In this case we present a patient with gingival recessions in the esthetic zone. We have considered the gingival and osseous recontouring as the most promising technique that would help us to achieve the most favorable outcome.

2. Case report

A healthy 41 year-old female patient was referred to our practice. She was primarily concerned with the esthetic appearance of her upper front teeth. Dental history reveals that she has been treated for chronic periodontitis two years ago. Treatment included non-surgical initial phase of periodontal treatment, followed by an open flap regenerative surgery. Periodontal treatment resulted in the pocket reduction and remission of her periodontal condition. However, post-operative gingival recession in the area of both upper right incisors now exceeds 5 mm. Porcelain fused to metal crowns were fitted 5 years ago, prior to periodontal treatment (Figure 1). Upper right central incisor is 2 mm over-erupted in comparison to the adjacent central incisor. No measurable periodontal pockets were present. We measured normal probing depth (PD) not exceeding 2 mm and zero bleeding-on-probing (BoP) at the time of the initial examination. Gingiva appears the be of thick biotype tested by transparency of the periodontal probe through the sulcus (TRAN). Width of the keratinized gingiva (GW) is sufficient for achieving stable results. Radiograph was obtained to analyze hard tissue structures and the coronal aspect of the periodontium (Figure 2).

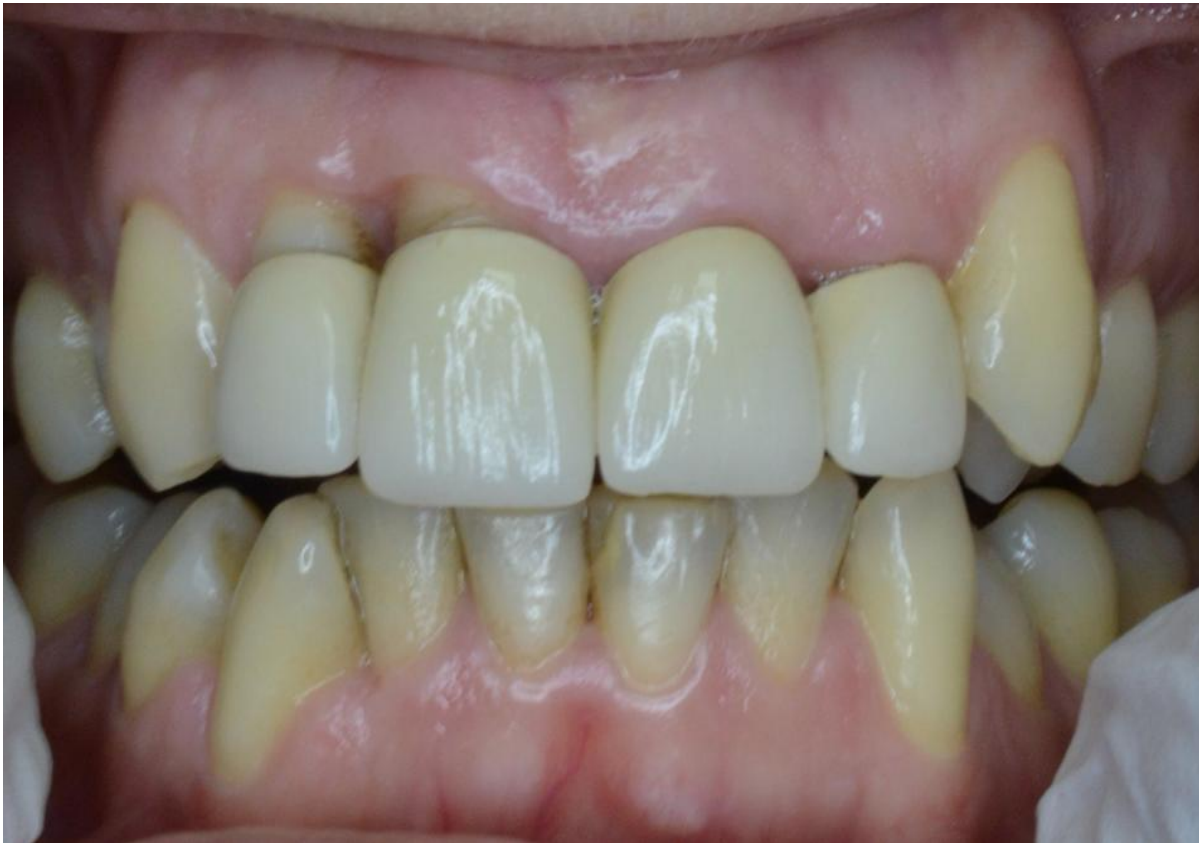

Figure 1. Initial pre-treatment photograph

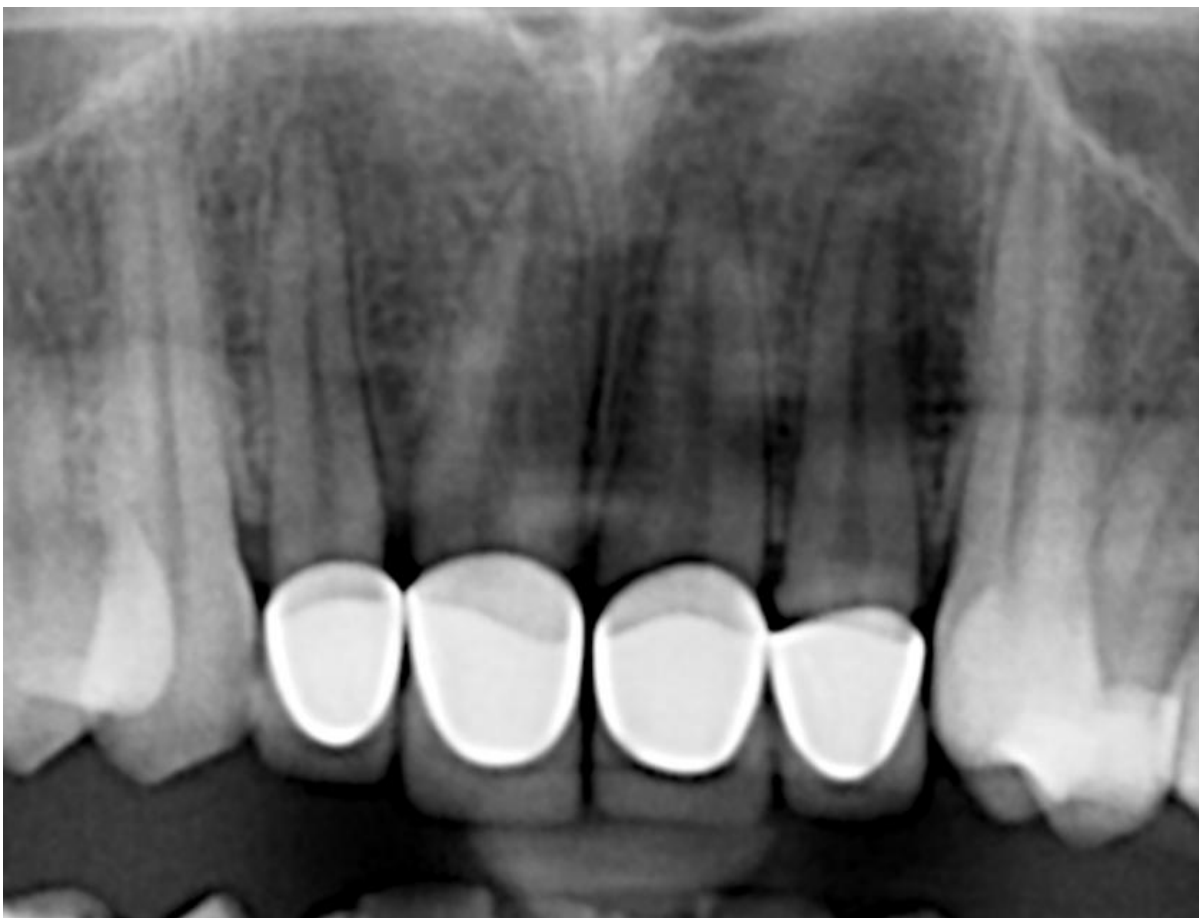

Figure 2. Pre-treatment radiograph

Treatment plan was divided into several stages. We have considered all the variables at the beginning of the treatment. Fixed restoration design, dimension and shape of the crowns were established during the planning stage (Figure 3). Firstly, our aim was to improve gingival esthetics and redefine biological width. Gingival recontouring was achieved with a mucoperiosteal flap and osseous recontouring. Straight after the surgery, patient was fitted with a temporary acrylic bridge in order to condition the soft tissues especially during the maximum growth phase. The patient was advised that a healing period of no less than 4 months is required.

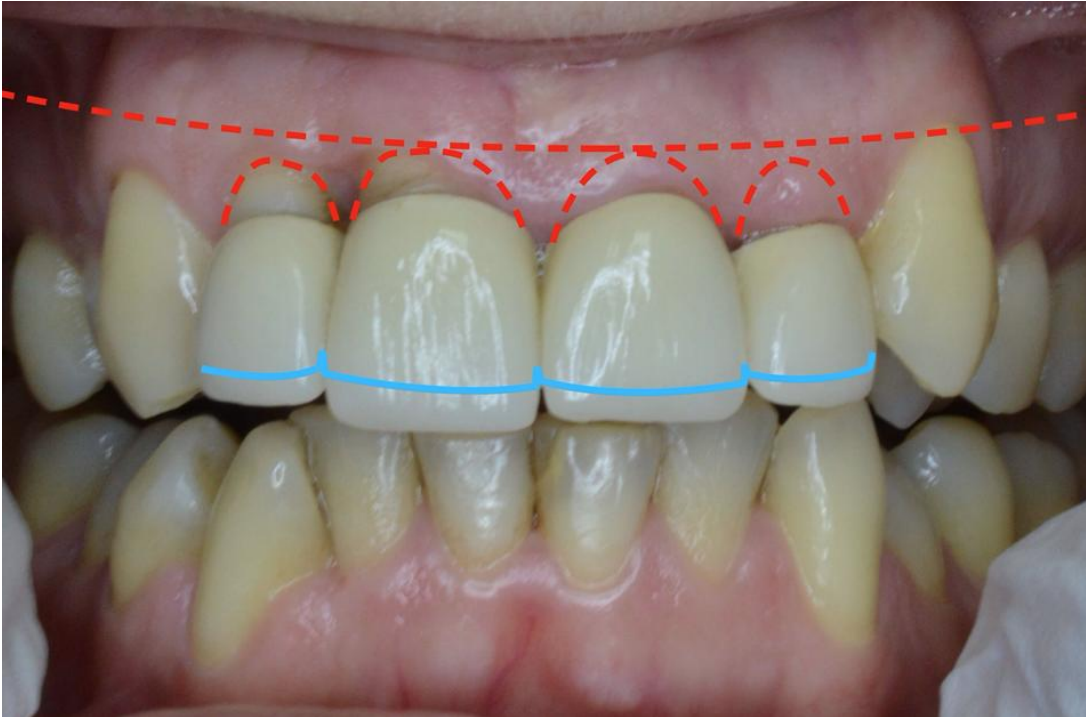


Figure 3. Treatment plan for crown lengths and gingival recontouring

Following the healing period, periodontal health was reexamined. The patient opted for a 4 unit zirconia-based ceramic bridge. Zirconia-based bridge was considered as a viable option for a young patient with high esthetic expectations. Since there is a history of periodontal disease with a tendency to over-eruption, bridge also seems to be a reasonable choice compared to single crowns. All incisors were endodontically treated. Root canals were filled using a standard lateral condensation technique. In order to provide for esthetically pleasing result, we have decided for a heavy shoulder preparation with strictly equigingival margin. Margin design will also be essential during the periodontal maintenance phase. Zirconia framework was digitally designed and then milled by a computer-aided design and computer-aided manufacturing (CAD/CAM) milling machine. Bridge will serve as a splint in order to prevent over-eruption and increased mobility. Patient was reviewed at one year follow-up examination. Final restoration is of comparable dimension to the original one, although crowns are now more apically positioned. Front area is slightly retruded and canines became more prominent. All that, together with newly defined gum line results in esthetically more pleasing appearance (Figure 4).

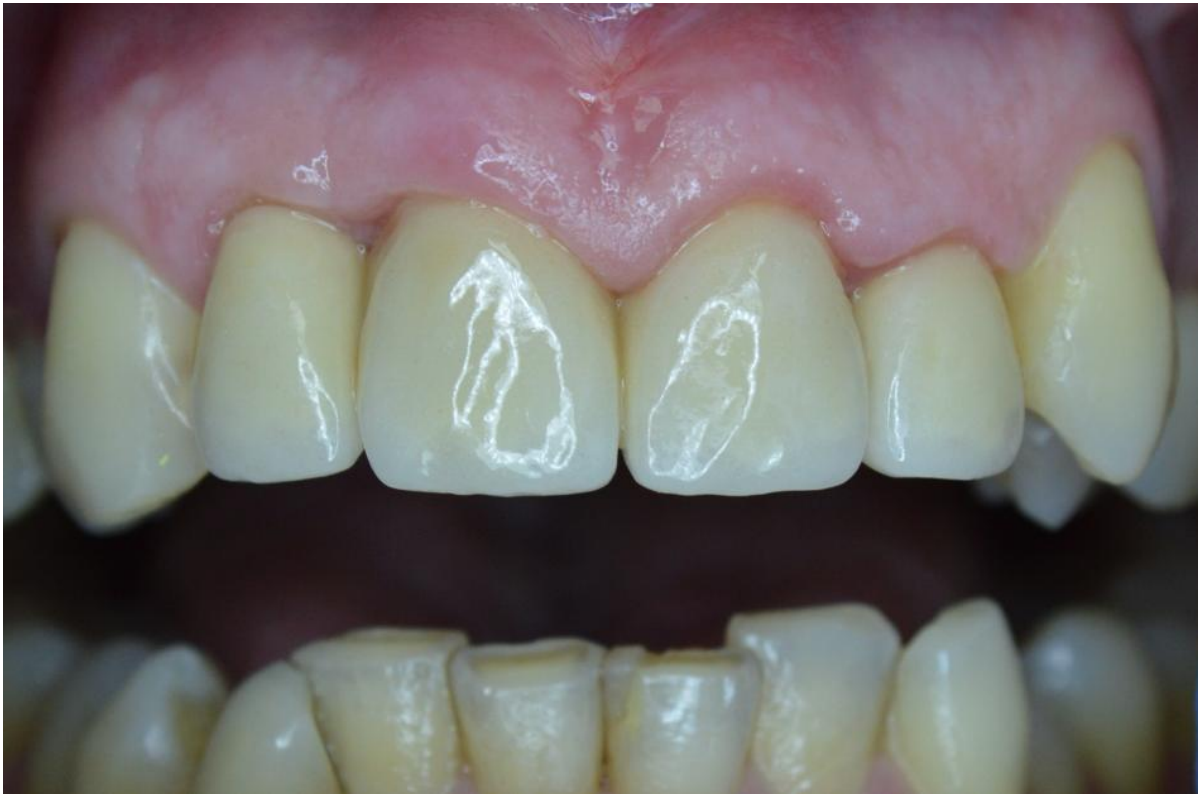

Figure 4. Photograph at one year follow-up

3. Discussion

The aim of the presented case was to provide insight into multidisciplinary approach that is required when managing cases positioned at the perio-prosthetic interface. The dimensions of the soft and hard tissues are important factors that have direct impact on the outcome of the periodontal and restorative treatments. Esthetically exposed area has particularly narrow tolerance for errors (5). Coronally advanced flap procedure for root coverage may have been considered in this case. Since there was a need for a new prosthodontic restoration, we opted for a gingival and osseous recontouring as a more predictable option. Zucchelli et al. (6) published a study where they describe standardized approach in treatment of two esthetic cases requiring crown-lengthening. Authors advocate the use of early postsurgical temporization, especially for shaping the interdental papillae. Pontoriero et al. (7) discusses different tissue biotypes and their influence on the outcome of restorative treatment. Baldi et al. and Hwang et al. observed that the thick gingival biotype yields more predictable results in regaining gingiva after resective osseous surgery and recession coverage (8,9). Patients with thin gingival biotype on the other hand are more disposed to the soft tissue loss in case of periodontal inflammation and after root coverage (8,10). Robbins (11) published a case where simple gingivectomy was performed for crown lengthening. After the healing period, tissues have reportedly rebounded to their pre-operative levels. Stable gingival recontouring was finally accomplished by mucoperiosteal flap and resective osseous surgery. Author claims that in order to achieve predictable results, the dentist must have a clear understanding of the biologic width.

4. Conclusion

This case indicates that under certain conditions, resective approach in treatment of gingival recessions may provide more favorable and more predictable results compared to regenerative surgical techniques. Clinical success is often determined by careful treatment planning that accounts for numerous periodontal, prosthodontic and esthetic implications.

References

1. Pini-Prato, G. (2011). The Miller classification of gingival recession: limits and drawbacks. *Journal of Clinical Periodontology*, 38(3), 243–245.
2. Paolantonio, M. (2002). Treatment of gingival recessions by combined periodontal regenerative technique, guided tissue regeneration, and subpedicle connective tissue graft. A comparative clinical study. *Journal of Periodontology*, 73(1), 53–62.
3. Zucchelli, G. De Sanctis, M. (2000). Treatment of multiple recession-type defects in patients with esthetic demands. *Journal of Periodontology*, 71(9), 1506–1514.
4. Laupacis, A. Wells, G. Richardson, W.S. Tugwell, P. (1994). Users' guides to the medical literature. V. How to use an article about prognosis. Evidence-Based Medicine Working Group. *Journal of American Medical Association*, 272(3), 234–237.
5. Stein, J.M. Lintel-Höping, N. Hammächer, C. Kasaj, A. Tamm, M. Hanisch, O. (2013). The gingival biotype: measurement of soft and hard tissue dimensions - a radiographic morphometric study. *Journal of Clinical Periodontology*, 40(12), 1132–1139.
6. Zucchelli, G. Mazzotti, C. Monaco, C. (2015). A Standardized Approach for the Early Restorative Phase After Esthetic Crown-Lengthening Surgery. *International Journal of Periodontics and Restorative Dentistry*, 35(5), 601–611.
7. Pontoriero, R. Carnevale, G. (2001). Surgical crown lengthening: a 12-month clinical wound healing study. *Journal of Periodontology*, 72(7), 841–848.
8. Baldi, C. Pini-Prato, G. Pagliaro, U. Nieri, M. Saletta, D. Muzzi, L. et al. (1999). Coronally advanced flap procedure for root coverage. Is flap thickness a relevant predictor to achieve root coverage? A 19-case series. *Journal of Periodontology*, 70(9), 1077–1084.
9. Hwang, D. Wang, H-L. (2006). Flap thickness as a predictor of root coverage: a systematic review. *Journal of Periodontology*, 77(10), 1625–1634.
10. Ericsson, I. Lindhe, J. (1984). Recession in sites with inadequate width of the keratinized gingival An experimental study in the dog. *Journal of Clinical Periodontology* [Online] Available: <http://onlinelibrary.wiley.com/doi/10.1111/j.1600-051X.1984.tb00837.x/full>
11. Robbins, J.W. (2000). Esthetic gingival recontouring - a plea for honesty. *Quintessence International*, 31(8), 553–556.